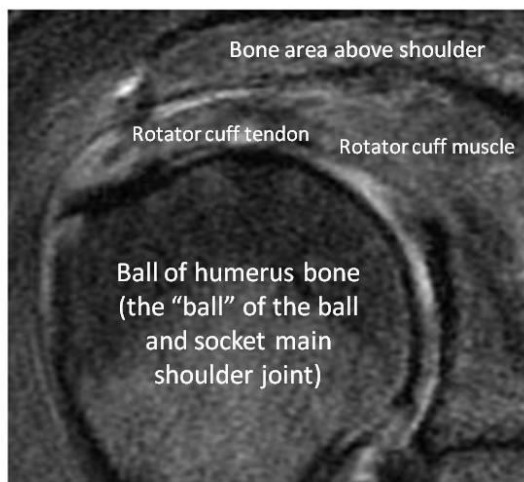


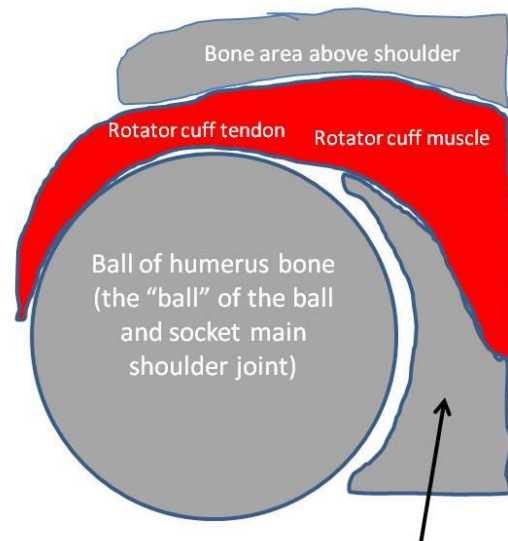
2 Year Follow-up on Full Thickness, non-retracted Rotator Cuff Tear Treated with Stem Cells

In keeping with some of the long-term treatment updates of our study patients this past week, this is the case of an elderly woman with a full thickness tear of her rotator cuff who had 100% relief through the injection of her own stem cells into the tear rather than surgery. The patient had severe pain and was basically unable to lift her shoulder. Because the tear wasn't retracted (the two ends of the tears were still together), she was placed into one of our studies as she was high risk for surgery. We injected her own cultured stem cells into the tears under imaging guidance. She had fairly rapid (1-3 months) complete recovery with return of full function of the shoulder and she needed no immobilization (blue pillow and sling). The big question was if this result would hold or if the repair tissue was flimsy and would soon re-tear. Here is her 2 year MRI. She is still reporting 100% resolution of her symptoms (she's now 80 years old) and her MRI shows that her rotator cuff tears still look largely resolved. To better understand what happened with her MRI and why it looks better now (as it did months after the injection), some basic MRI 101 classwork is in order.

2.04.2008 COR MRI



COR MRI. ET=7, TR=2350, TE=62.2

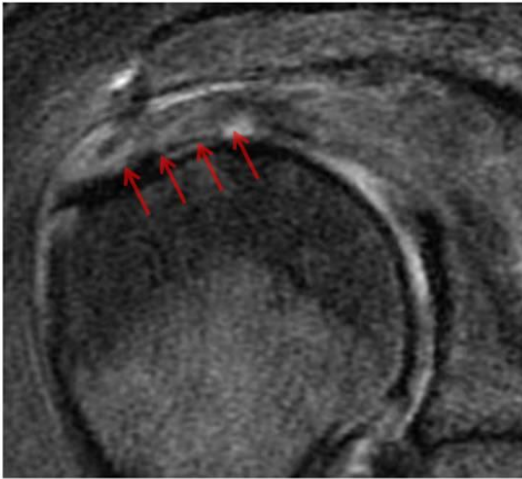


Acetabulum or shoulder joint socket

The image above is this patient's pre-injection coronal MRI. A coronal MRI slice is one that lets you look from the front or the back. Here you can see the MRI on the left and the diagram of the MRI to the right. The rotator cuff tendon is the area of interest. The rotator cuff like any muscle has two parts, the muscle belly and the part that attaches the muscle to the bone, the muscle tendon. Rotator cuff tears commonly occur at the muscle tendon area. In addition, MRI images

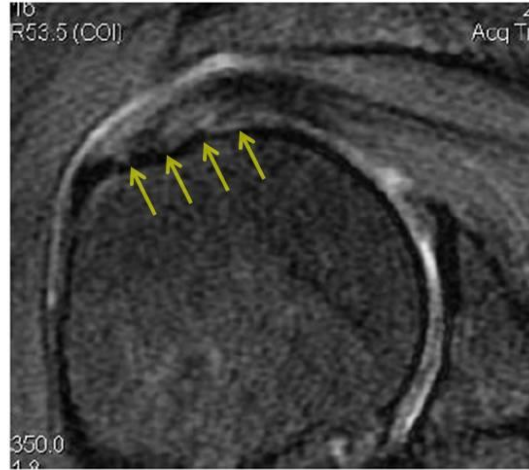
come in many different flavors, some show water as bright or a lighter color, which is what's being shown here in these PDFS sequences. So on this image, a darker appearing tendon is good, one with light spots in it is bad. A normal rotator cuff tendon in this type of MRI sequence would be a uniform darker color or black (depending on age).

2.04.2008 COR MRI



COR MRI. ET=7, TR=2350, TE=62.2

6.24.2010 COR MRI



COR MRI. ET=7, TR=2350, TE= 62

Now for the patient MRI's. Above on the left is an MRI taken 2 months before her stem cell injection in April 2008, the image on the right is her 2 year follow-up MRI. The left MRI shows the rotator cuff tendon (red arrows) which is bright in color and mottled in appearance. This means that it's a full thickness rotator cuff tendon tear with severe degeneration (she's 78 years old at the time of this picture). To the right is her two year follow-up MRI showing a darker appearing rotator cuff tendon (yellow arrows) without any light color that goes all the way through the tendon (she's 80 years old in this picture). Clearly an improvement that's still holding and demonstrated not only by her reports of no pain and full function, but also objective MRI imaging two years later.